

# Three-dimensional diagnosis & treatment planning: The use of 3D facial imaging and 3D cone beam CT in orthodontics and dentistry

By William E. Harrell, Jr, DMD



*“Three-dimensional imaging and its use ‘over time’ provides the true anatomical data necessary to expand clinical practices and researchers into evidence-based diagnosis in dentistry...”*

**T**he goal of diagnosis and treatment planning in dentistry is to decide a course of treatment based on the evaluation of the initial condition of the patient’s anatomy from various types of imaging sources. These imaging sources (x-rays, photographs, etc) have traditionally been from two-dimensional film-based systems and more recently from 2D digital imaging systems. Imaging in dentistry is used for developing various treatment plans, monitoring treatment response, and for evaluation of treatment outcomes.

In orthodontics, imaging of the patient’s anatomy has traditionally been evaluated from two-dimensional (2D) imaging sources such as: 2D cephalometric X-rays (lateral, frontal, etc), panoramic and other x-rays, 2D facial and intra-oral photographs, etc. These 2D images and the resultant 2D tracings have then been compared to “standards” or “norms” created from data which differ by age, sex, race, etc. The limitations of 2D cephalometric projections have been known since its inception.<sup>1</sup> Geometric errors of projection not only affect X-ray projections but also affect measurements made on 2D photographs and 2D video imaging.

Evaluating the “Anatomic Truth” of our patient’s anatomy in 3D has traditionally been limited to evaluating the patient “live” in the chair and by the evaluations of dental study models (either plaster or 3D digital representations). New 3D technologies (3D facial scanning and 3D cone beam CBCT - also known as Conebeam Volumetric Tomography (CVCT)) are just beginning to be introduced into the dental and orthodontic communities in order to evaluate the three-dimensional anatomic relationships of the patient’s true anatomy. The 4th dimension, which is time, consists of evaluating the three-dimensional relationships as they change over

time. This could be in “real time” such as function, para-function, chewing, smiling, etc or “over a period of time” which could be days, weeks, months or years, such as aging, degenerative changes, traumatic changes, surgical changes, etc.

It is essential to evaluate, analyze and use accurate imaging data that represents the “anatomic truth” of the patient’s anatomy. The American Dental Association defines evidence-based practice as an approach to oral health care that requires the judicious integration of systematic assessments of clinically relevant scientific evidence, relating to the patient’s oral and medical condition and history, with the dentist’s clinical expertise and the patient’s treatment needs and preferences.<sup>2</sup>

Evidence-based should be divided into two areas: 1) Evidence-based Diagnosis (EBD); and 2) Evidence-based Treatment (EBT).

Evidence-based Diagnosis should be based on the best available data (i.e. imaging, diagnostic setups, tests, etc) for the time. Imaging should try and represent the “Anatomic Truth” so that diagnosis is based on accurate information. Diagnosis is the KEY to treatment planning, treatment monitoring and eventual actual treatment. Evidence-based Treatment should be based on the best available information of the time. There are many different types of “Treatment Philosophies” that are based on extensive clinical experience and scientific research. So EBT may vary between practitioners. What works well in one doctor’s hands may or may not work well for someone else. They may get to the same place as their goal, but they may get there differently. This seems to be the area of Evidence-based dental practice that creates the most confusion. “You don’t know what you don’t know and you don’t know what you can’t see”.

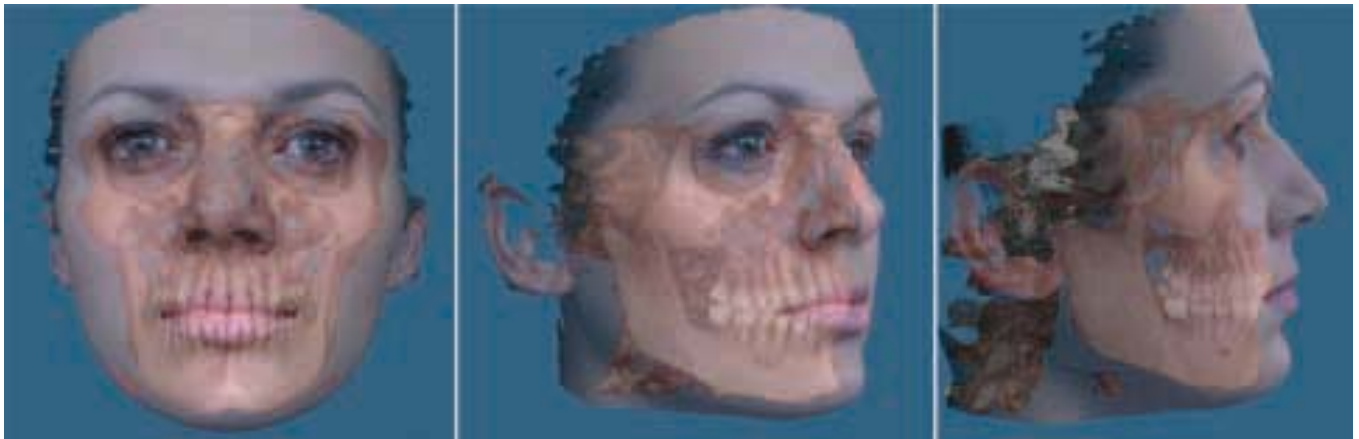

Figure 1. Combination of the i-CAT cone beam scan of the teeth and skeletal structure with the 3dMD face scan that has been co-registered. This 3D model can be rotated, viewed and analyzed from any angle the doctor desires.

Three-dimensional imaging and its use “over time” (the 4th dimension) provides the true anatomical data necessary to expand clinical practices and research into evidence-based dentistry. Dental Informatics and Orthodontic Informatics is that area of dentistry that deals with the optimal creation, integration and use of biomedical information, as it relates to dentistry and orthodontics, which includes accurate imaging of our patients. The American Dental Association is the national and international leader in the development of standards, technical reports and guidelines for materials, information and technology impacting the practice of dentistry and the safety and health of the public.<sup>3</sup> In order to understand the importance of these standards and guidelines in dentistry and orthodontics, a few terms should be defined:

- Information Technology is a term that encompasses all forms of technology used to create, store, exchange and use information in its various forms (business data, voice conversations, still images, motion pictures, multimedia presentations and other forms, including those not yet conceived). It is a convenient term for including both telephony and computer technology in the same word. It is the technology that is driving what has often been called “the information revolution”.
- Medical Informatics is a term that is defined as “the well established scientific field of medicine that deals with biomedical information, data, and knowledge - their storage, retrieval, and optimal use for problem-solving and decision making”.<sup>4</sup>

Table 1.

Examination	Effective radiation dose (micro Severts, Sv)	Equivalent natural background radiation
Panoramic	3 to 11	half to one day
Cephalogram	5 to 7	half to one day
Occlusal Film	5	half day
Bite wing	1 to 4	half day
Full Mouth Series	30 to 170	4 to 21 days
TMJ Series	20 to 30	3 to 4 days
CBCT Exam	40 to 135	4 to 17 days
Medical Exams		
Chest X-ray	100	10-12 days
Mammography	700	88 days
Medical CT	8,000	1,000 days

*Courtesy James Mah, DDS, MSc, X-ray Imaging and Oral Healthcare, 2006*

- Dental Informatics is a subdivision of medical informatics and deals with information in the field of dentistry.
- Orthodontic Informatics was first described in an article in AJODO Sept 2002, by Drs Harrell, Hatcher, & Bolt<sup>5</sup> as a subdivision of dental informatics and deals with the storage, retrieval, sharing and optimal use of orthodontic, orthognathic and dentofacial orthopaedic information of the craniofacial region for decision making (diagnosis) and problem solving (treatment planning).
- Imaging Informatics is also a subdivision of health informatics which plays a significant role in orthodontics and dentistry because, as clinicians and researchers, we use imaging every day in our practices.

Shortliffe<sup>4</sup> describes the role of imaging in health care (imaging informatics) as “a central part of the assessment of response to treatment and estimation prognosis. In addition, imaging plays important roles in medical communication and education as well as research.”

In 2005, the author became one of the first orthodontists in private practice to routinely use 3D facial image capture (3dMD, Atlanta, GA) and the first practitioner in the state of Alabama to use cone beam Volumetric Tomography or cone beam CT (i-CAT®, Imaging Sciences). 3D face scans (3dMD) use no radiation and produce an accurate 3D model of the patient’s facial contours (RMS < 0.5mm) with phototexture in 1.5 milliseconds capture time.

Cone beam CT (CBCT), also known as Cone beam Volumetric Tomography (CBVT), produces accurate 3D image data of the craniofacial region, with low radiation dose. People are exposed to radiation from natural sources all the time. The average person in the US receives an effective dose of about 3,000 micro Sieverts (Sv) per year (~8 micro Sv per day) from natural sources such as cosmic radiation from outer space and sources in the soil. The largest source of background radiation comes from radon gas in our homes which is about 2,000 micro Sv per year. Radon exposure varies from one location to another. Altitude also plays an important role as people living at higher elevations can receive up to 1500 micro Sv more per year than those living at sea level. The dose from cosmic X-rays during a coast to coast flight in the US is about 30 Micro Sv. Table 1 compares common dental procedures with comparable natural background exposures and selected medical examinations. Note that dental examinations are equivalent to less than one day to a couple of weeks of natural background radiation.

3D facial image capture and cone beam CT can be combined to create a "virtual 3D patient" (Figure 1) which the orthodontist and referring dentist can then evaluate in an anatomically true fashion. These 3D models are interactive and can be rotated to any view for more complete diagnosis and treatment planning.

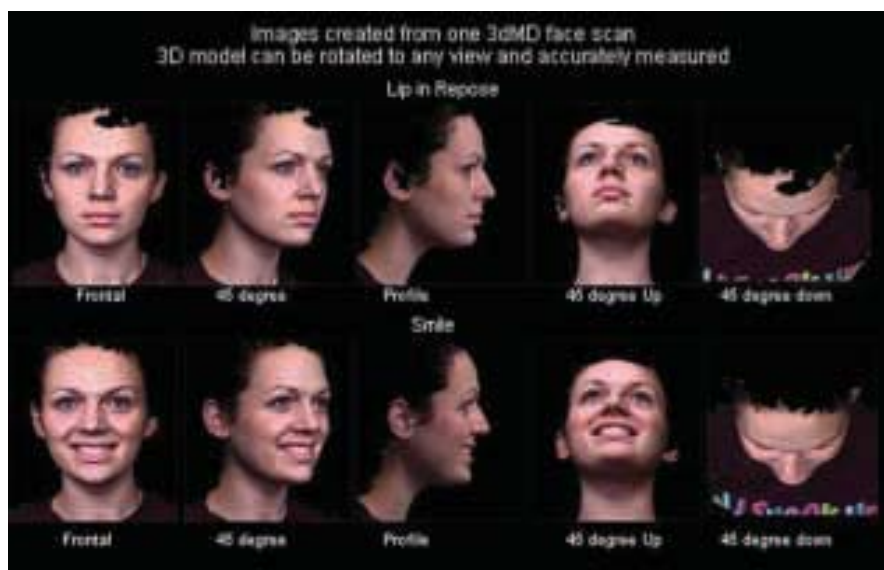

Figure 2. Examples of uses of the 3D face scan to evaluate the patient's 3D facial soft tissue relationship in lips relaxed and smiling views. These are 2D images created from one 3D capture with lips relaxed position and one 3D capture in full smile. Note the narrowness of the buccal segments of the teeth in relation to the smile.

### 3D surface scanning

Multiple planar 2D views can be created from one 3D scan (Frontal, Right and Left Lateral, 45 degree views, Submental, Top, etc) (Figure 2). The true value in a 3D facial surface scan relates to the ability to assess and monitor patient treatment without the need for radiation. There are a number of treatments that can be quantitatively evaluated from the facial surface because there are noticeable changes to the patient's face - i.e. orthodontic extrac-

tion/non-extraction, anterior torque requirements, smile aesthetics, different appliances: such as palatal expansion devices or Herbst appliances, orthognathic and reconstructive surgical treatment, etc (Figures 3a and 3b). Also as a complementary technology to CBCT, 3D facial surface scans can compensate for soft tissue deformations caused by patient positioning restraints such as a chin cup or facial surface errors of the CBCT caused by patient movement.

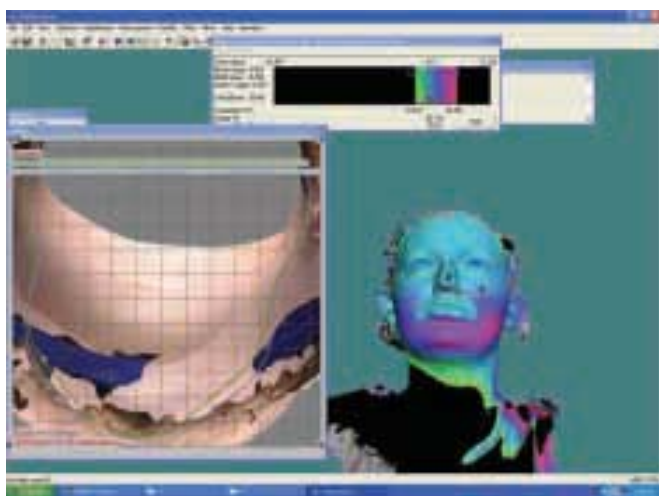


Figure 3a. This figure shows the differences between pre- and post-mandibular advancement orthognathic surgery. The image on the left shows that cross section of the soft tissue movement and the colour histogram on the right shows the amount of movement, by colour variations, between the pre- and post-op 3D captures.

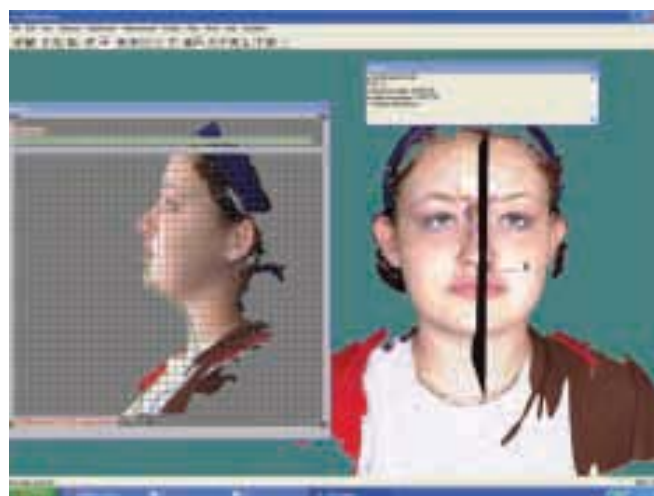

Figure 3b. Right images are the pre- and post-mandibular advancement 3D images co-registered at the forehead area. The midsagittal plane is shown. The left image shows the sagittal slices of the pre- and post-surgical 3D images and the changes which have occurred to the soft tissue.

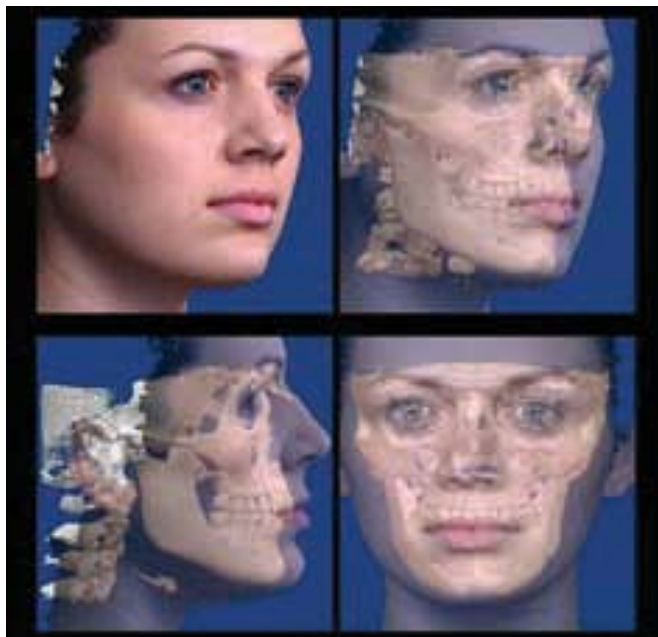

Figure 4a. Co-registered 3D facial scan and 3D x-ray data as seen from different views.

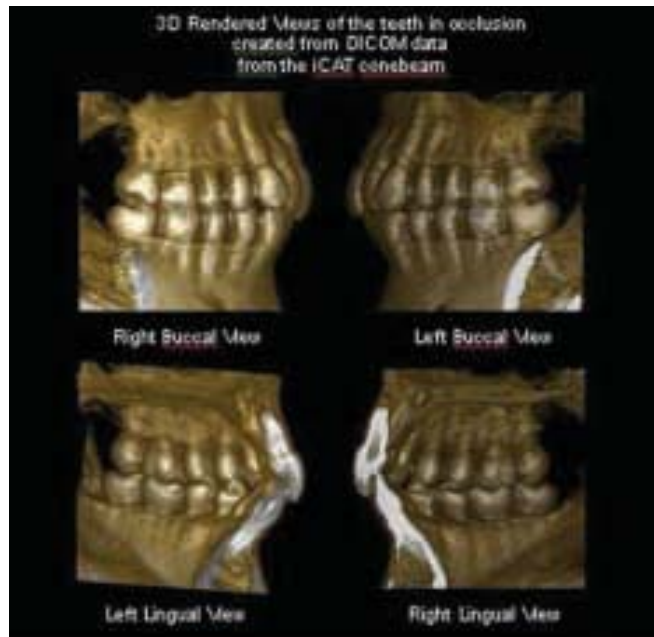

Figure 4b. 3D rendered teeth created from the 3D x-ray scan (Cone beam CT).

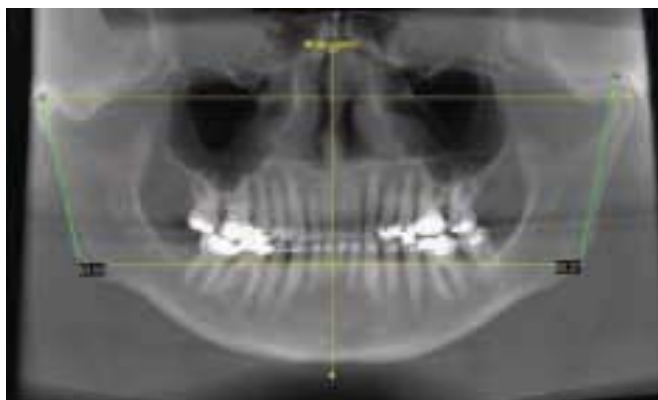


Figure 5a. A panoramic view created from i-CAT cone beam scan. The panoramic cut plane is user-defined, creating an accurate panoramic cut with no superimposition of structures outside the thickness of the panoramic cut plane. Cut thickness is 15mm.

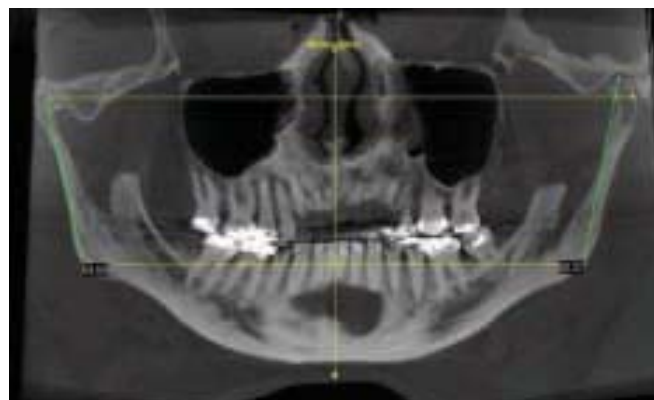

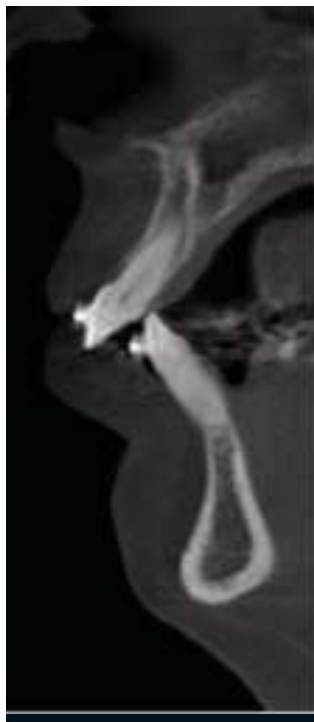Figure 5b. A thinner Panoramic cut of 0.3 mm, for better assessment of mandibular canal and alveolar bone height along the slice plane.

### Cone Beam Computed Tomography (CBCT)

Cone beam CT is a new form of computed tomography which uses different source detectors and a different type of acquisition than traditional fan-beam medical CT. Conventional “fan-beam” CT images the patient as a series of axial cuts, like a fan, and are captured as individual slices, which can be stacked into a 3D volume or viewed in cross sections. The voxel size is dependent on the scan thickness, which is usually between 1 - 5 mm. This produces anisotropic voxels, which means the width and thickness are

equal, but the height measurement (axial slice thickness) may vary between 1-5 mm. Anisotropic voxels are like a rectangular box, equal on 2 sides and the third side varies in thickness (i.e. 0.1 x 0.1 x (varies between) 1.0 - 5.0 mm). The radiation dosage of conventional CT is much higher than cone beam tomography (Table 1). Cone beam volumetric tomography uses one rotational sweep of 360 degrees. The scan times vary between 8.5 (or less) to 75 seconds, depending on the field of view and the CBCT unit used. The radiation dose for a complete volume of the maxillofacial area is usually less

than a periapical full mouth survey (Table 1). One of the biggest advantages of cone beam CT is that the doctor can get much more accurate information from one cone beam scan than the multiple 2D views we traditionally use with much less radiation. The voxel size of CBCT is 0.1 - 0.4 mm in all 3 planes of space (the X,Y and Z planes) and produces an isotropic voxel size which are equal in width, thickness and height. Isotropic voxels are like a square box with all sides having the same dimension (i.e. 0.1 x 0.1 x 0.1 mm). The image data output can be sliced into various planes (axial, coronal, sagittal) or



viewed as a 3D volume (Figure 4a and 4b). Accurate 1:1 measurements can be made along any slice plane and on any part of the anatomy.

Cone beam CT can allow for different views to be created from one scan. All of the views are accurate and not subjected to geometric projection errors that are inherent in traditional 2D images. Sophisticated computer algorithms correct these geometric distortions and, for example, a reconstructed panoramic view can be created. This type of panoramic view is different from what traditional film-based or digital panoramic units create; as there is no superimposition of anatomic structures, the panoramic slices can be as thick or as thin as you wish and the teeth and TMJs are an accurate panoramic view as the doctor defines the path of the panoramic cut through the mandible

Figure 6. Anterior cross section from the initial cone beam scan. Alveolar bone width and torquing requirements for the anterior teeth can be accurately assessed.

and maxilla (Figure 5). With the thinner slices, one can evaluate the relationship of the lingual nerve for evaluation of extraction, implants, etc. Evaluation of implant receptor sites based on the understanding of available bone, the density of the bone (which can be determined by measuring the Hounsfield units), avoidance of important anatomical structures, restorative and aesthetic requirements are all important areas to evaluate prior to therapy. Cross sections of the anterior teeth can allow the doctor to evaluate the alveolar bone width and heights, and plan the orthodontic torquing needs of the specific patient (Figure 6). Posterior cross sections can allow for bucco-lingual skeletal and dental evaluations of individual pairs of teeth. From the panoramic view, cross sections can be made for evaluation of implant placement, implant anchorage placement for orthodontics, etc. Position of impacted cuspids can be accurately assessed and treatment planned for proper attachment placement and directions of movement (Figures 7a and 7b). Walker, Enciso and Mah, using 3D cone beam localization, found

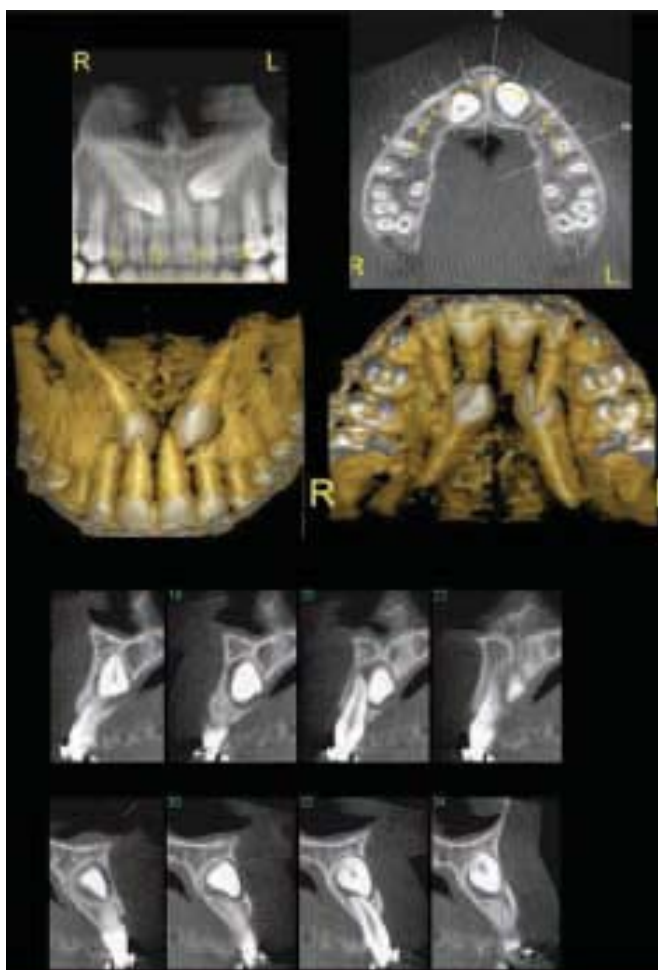


Figure 7a. Cross sections and rendered 3D views of impacted canines.

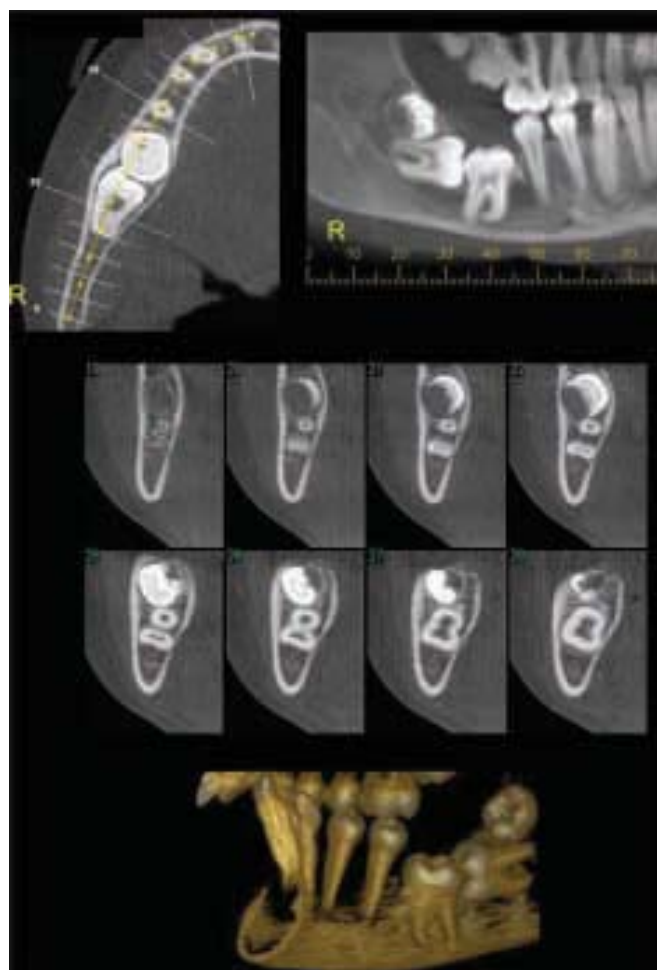
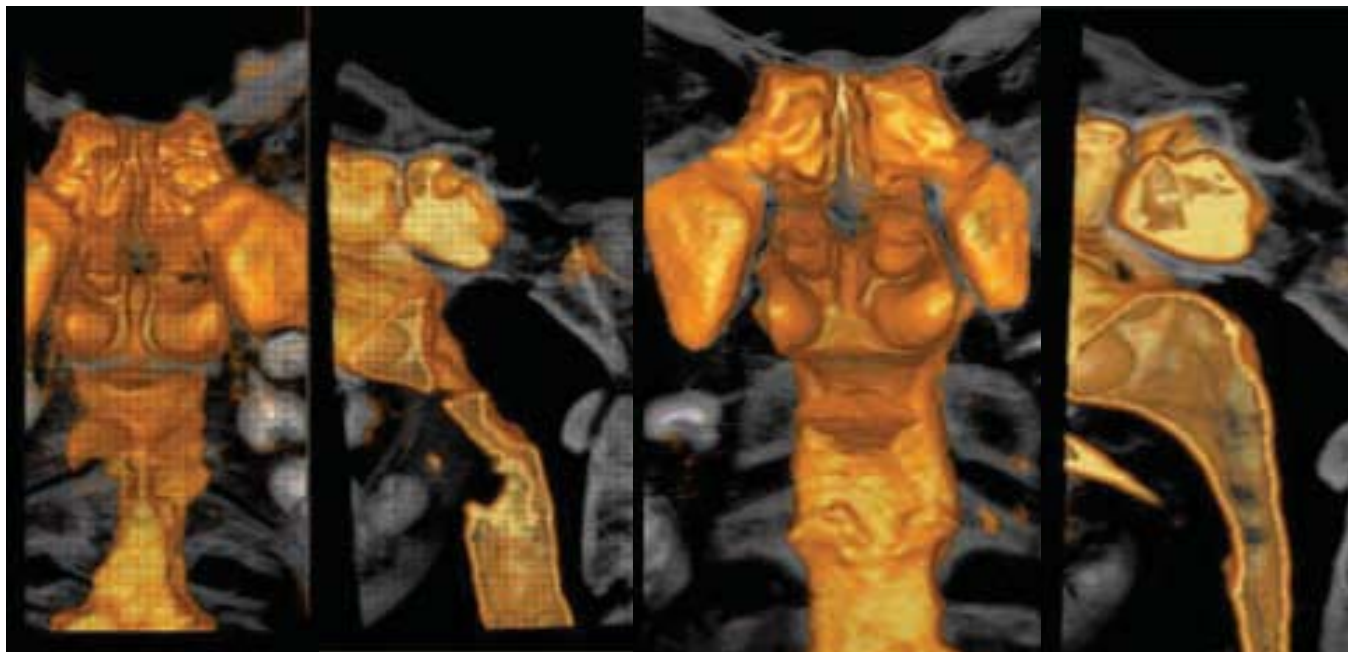


Figure 7b. Cross sections and rendered 3D views of impacted molars.



Figures 8a-d (left to right). Coronal view of constricted airway (orange), pre-adenoidectomy and tonsillectomy; Sagittal view of constricted airway (orange), pre-adenoidectomy and tonsillectomy; Coronal view of normal size airway (orange), after adenoidectomy and tonsillectomy; and Sagittal view of normal size airway (orange), after adenoidectomy and tonsillectomy.

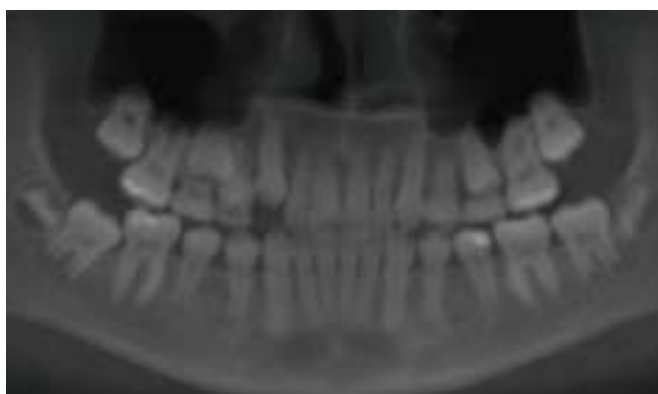

Figure 9a. Panoramic view. The abnormal position of the maxillary right 2nd bicuspid is not readily evident.

that incisor root resorption adjacent to the impacted canines were present in 66.7% of the lateral incisors and 11.1% of the central incisors, prior to any treatment.<sup>6</sup>

Studies using cone beam CT find significant changes in the TMJ are found in 15-20% of the cases prior to any treatment.<sup>7</sup> Figures 8a and 8b show constricted airway - pre-tonsil and adenoidectomy. Figures 8c and 8d show post surgery of airway, now normal size. Airway problems in young children can affect their craniofacial growth and development.<sup>8</sup> Sinus and airway analysis can also be easily evaluated from the same cone beam scan. Studies using cone beam CT have shown that 25% of patients have significant airway findings, including obstruction, lack of airway patency, sinus inflammation, polyps, nasal deviation, etc.<sup>9</sup>

An abnormal eruption pattern of the maxillary right 2nd bicuspid is not evident in the panoramic view in Figure 9a.

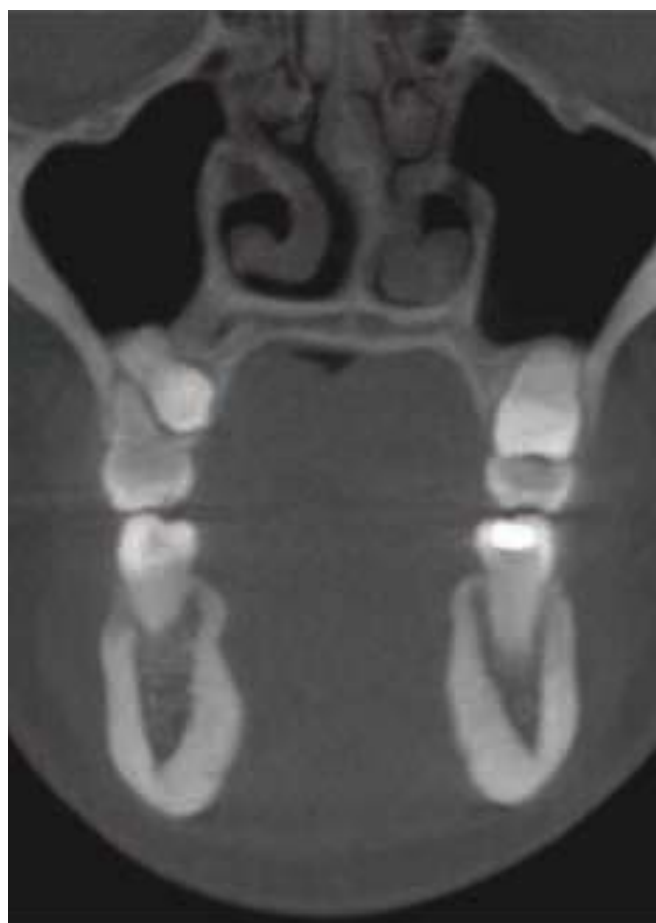

Figure 9b. The coronal section clearly shows the abnormal development of the maxillary right 2nd bicuspid.

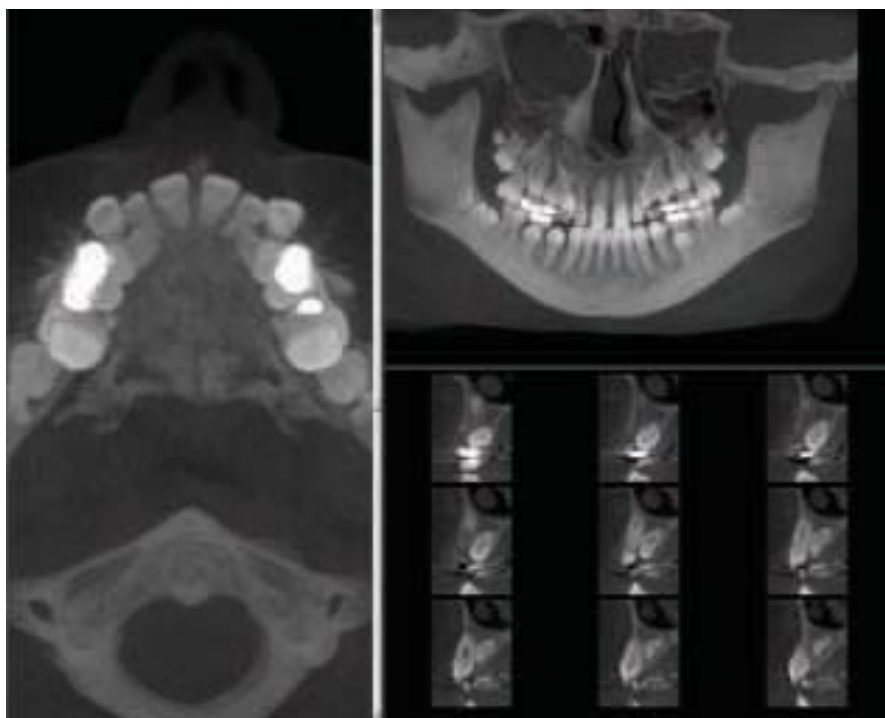


Figure 10 a (left). Transposed roots of Maxillary cuspids and 1st bicuspids; Figure 10b (right). Three Supernumerary teeth located superior to and affecting the eruption of the mandibular right central and lateral incisors.

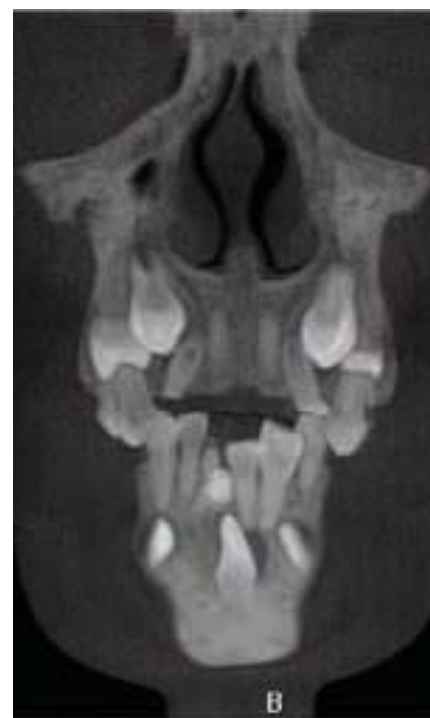

Figure 11 (right). TMJ views from the initial cone beam scan shows cystic and degenerative changes of the condyles. The sagittal views show the cyst in the right TMJ, small condyles and posterior displacement.

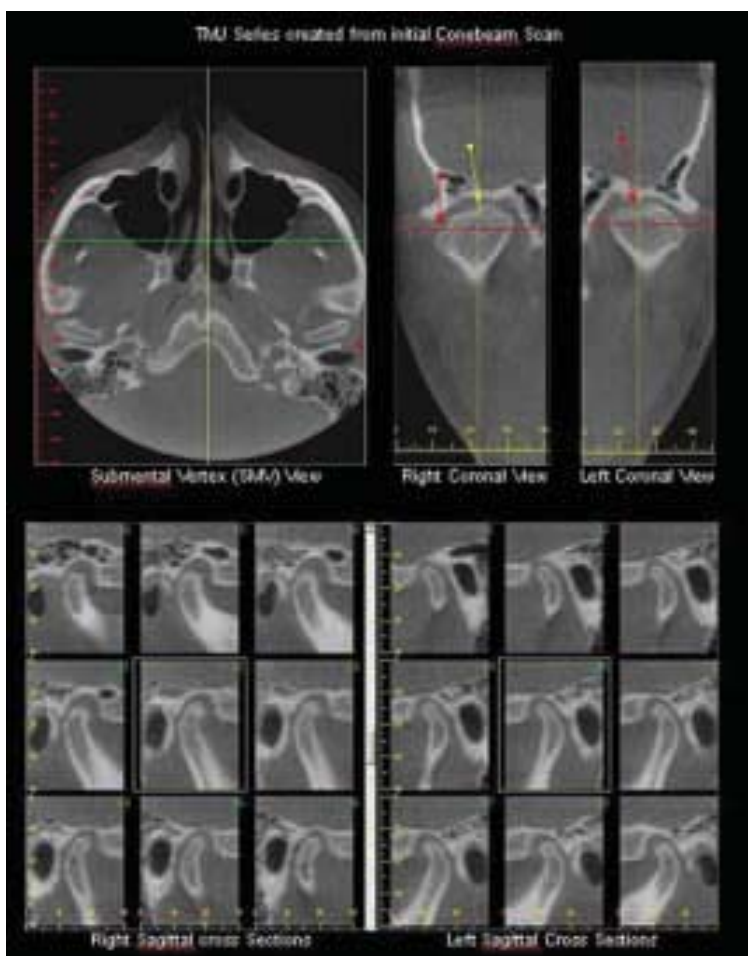


Figure 9b shows the coronal cross section view of the lingually developing maxillary right 2nd bicuspid. Other developmental abnormalities such as transposed roots of maxillary cuspids and 1st bicuspids (Figure 10a), supernumerary teeth in mandibular anterior area (Figure 10b), and TMJ degenerative joint disease (Figure 11) can be seen from any view.

The use of 3D imaging, along with evaluation of the 4th dimension of time, will improve diagnostics and treatment by increasing the understanding of the patient's true anatomical and biomechanical form and thus the anatomic and biomechanical truth. Figure 12 shows co-registered 3d facial images of 2 separate time points of the face when the patient was speaking. The 4th dimension of evaluating growth and aging changes would greatly increase our diagnostic and treatment planning ability. In order to accurately simulate treatment alternatives, the biomechanical relationship between the different facial/dental components (i.e. bone, teeth and soft tissues) must be defined in a physiologic manner. 3dMD's software has implemented a "springs & coils" based simulation model in which ~500,000 attachments define the relationship between the hard and soft tissue (Figure 13).



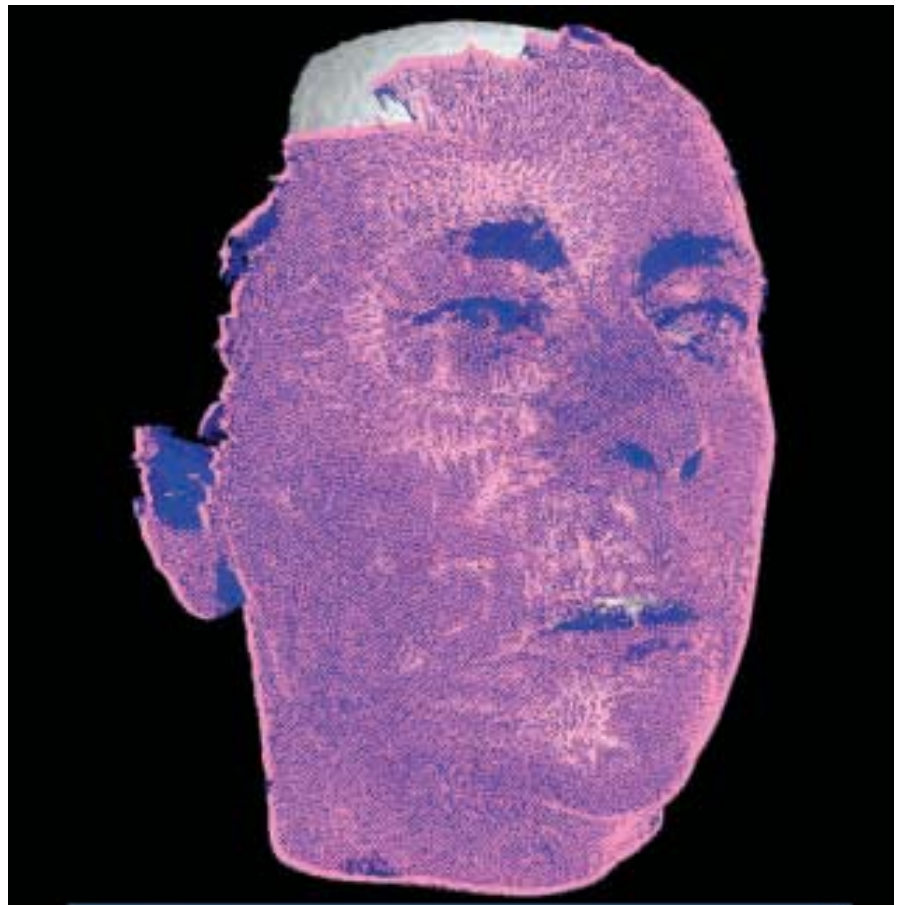
Figure 12. 4D capture of 3D facial images can be used to evaluate facial expressions, 3D facial changes in speech patterns, facial changes over time, etc. Individual time points of these changes in the face can be analyzed and measured by co-registering different time points and analyzing the changes that occur (Images Courtesy of 3dMD (www.3dmd.com), Atlanta, GA).

## References

1. Broadbent, BH. A new x-ray technique and its applications to orthodontia, *Angle Orthodontist*, 1: 45-66, 1931.
2. Ackerman, Marc, Evidence-based orthodontics for the 21st century. *JADA*;135:162-167, 2004. (The ADA Policy on Evidence-based Dentistry can be found at [www.ada.org/prof/resources/positions/statements/evidencebased.asp](http://www.ada.org/prof/resources/positions/statements/evidencebased.asp))
3. Harrell, WE, Stanford, S, Bralower, P. ADA initiates development of orthodontic informatic standards, *Am J Orthod Dentofacial Orthop.*, vol. 128, #2, pgs 153-156, 2005.
4. Edward Shortliffe, et., al., *Medical Informatics: Computer Applications in Health Care and Biomedicine*, 2nd Ed, Springer, 2001.
5. Harrell, WE, Hatcher DC, Bolt RL. In Search of anatomic truth: 3-Dimensional Digital modeling and the future of orthodontics, *Am J Orthod Dentofacial Orthop.*, vol. 122 #3, pgs 325-330, 2002.
6. Walker L, Enciso R, Mah J., *Am J Orthod Dentofacial Orthop.* Oct; 128(4):418-23, 2005.
7. Personal communication, Dr. Joe Caruso, Orthodontic Chairman, Loma Linda Univ.
8. McNamara, JA, Naso-respiratory function and craniofacial growth, Center for Human Growth and Development, Craniofacial Growth Series, The University of Michigan Symposium, 1979.
9. Redmond, R, et al. *The Cutting Edge*, JCO, vol 39, #7, July, 2005.

## About the author

*Dr William Harrell is a Board Certified Orthodontist practicing in Alexander City, Alabama, USA and is presently serving on the American Dental Association's (ADA) Standards Committee on Dental Informatics. He is a past member of the AAO's Council on Information Technology (COIT) and Past President and Vice President of the Alabama Orthodontic Association. Dr Harrell can be contacted at [drharrell@aol.com](mailto:drharrell@aol.com).*



Figures 13. "Virtual springs and coils" are attached to bone, teeth and soft tissues in an anatomical and biomechanical orientation for improvement of 3D simulation of tooth, bone and soft tissue movement ((Images Courtesy of 3dMD (www.3dmd.com), Atlanta, GA)).