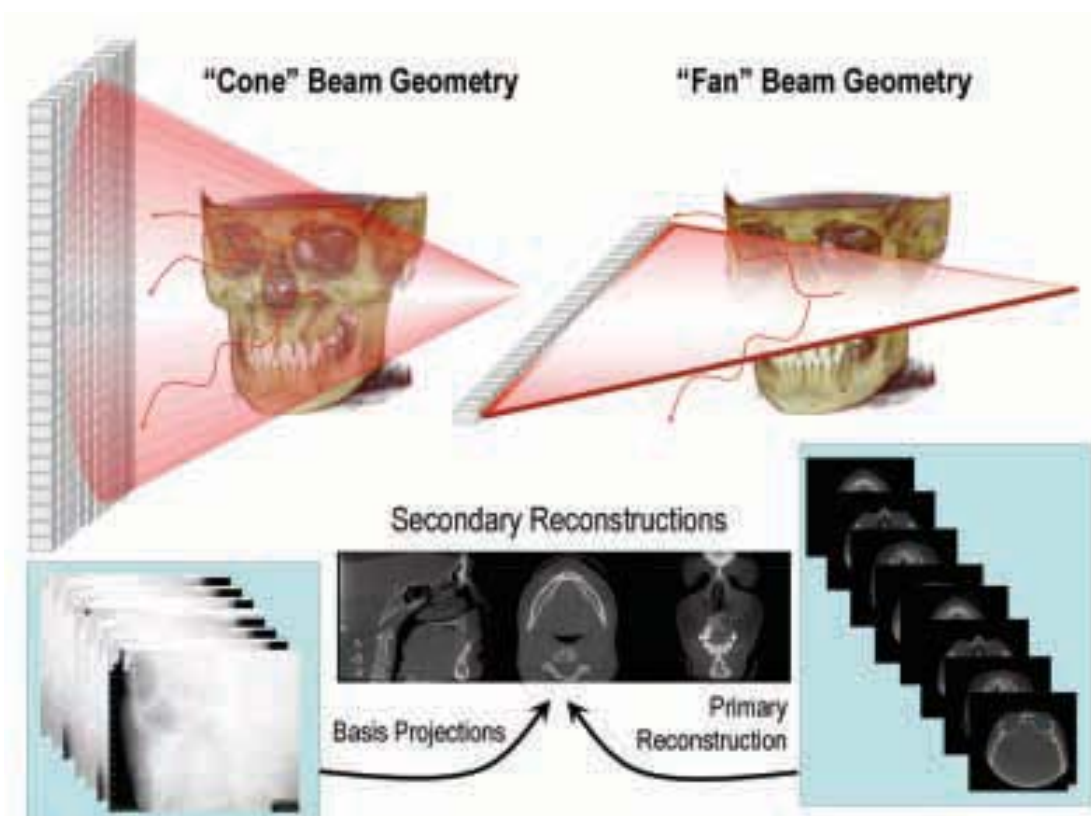


Cone beam computed tomography: A paradigm shift for clinical dentistry

By William C. Scarfe BDS, FRACDS, MS, Dipl. ABOMR and
Allan G. Farman BDS, PhD, DSc, MBA, Dipl. ABOMR, Dipl. JBOMR



“The unprecedented interest in CBCT from all fields of dentistry is because it has created a revolution in maxillofacial imaging - facilitating the transition of dental imaging from 2D to 3D...”



Imaging is an important diagnostic adjunct to the clinical assessment of the dental patient. The introduction of panoramic radiography in the 1960's and its widespread adoption throughout the 1970's and 80's heralded major progress in dental radiology - providing clinicians with a single comprehensive image of both jaws and maxillofacial structures. However both intraoral and extraoral procedures, used individually or in combination, suffer from the same inherent limitations of all planar two-dimensional (2D) projections - magnification, distortion, superimposition and misrepresentation of structures. Numerous efforts have been made towards three-dimensional (3D) radiographic imaging (e.g.

Figure 1. X-ray beam projection scheme comparing acquisition geometry of conventional or "fan beam" (right) and cone beam imaging geometry (left) and resultant image production. In cone beam geometry (left) multiple basis projections for the projection data from which orthogonal planar images are secondarily reconstructed. In fan beam geometry, primary reconstruction of data produces axial slices from which secondary reconstruction generates orthogonal images. The amount of scatter generated (sinusoidal lines) and recorded by cone beam image acquisition is substantially higher reducing image contrast and increasing image noise.

stereoscopy, TACT™) and while computed tomography has been available, its application in dentistry has been limited because of cost, access and dose considerations. The introduction of cone beam computed tomography (CBCT) specifically dedicated to imaging the maxillofacial region heralds a true paradigm shift. The unprecedented interest in CBCT from all fields of dentistry is because it has created a revolution in maxillofacial imaging - facilitating the transition of dental imaging from 2D to 3D images and expanding the role of imaging from diagnosis to image guidance of operative and surgical procedures via third party applications software.

The purpose of this article is to provide an overview of this CBCT technology and review its capabilities with specific applications in clinical practice.

CBCT image production

“Cone-beam” computed tomography (CBCT) is accomplished using a rotation in which a pyramidal- or cone-shaped x-ray beam is directed towards an area x-ray detector on the other side of the patient’s head. Multiple 2D projection images are acquired for a field of view (FOV) selected according to the region of interest (ROI). This varies from a traditional medical CT which uses a fan shaped X-ray beam in a helical progression acquiring individual image slices of the FOV and then stacks the slices to obtain a 3D representation. Each slice requires a separate scan and separate 2D reconstruction (Figure 1). Because CBCT exposure incorporates the entire FOV, only one rotational sequence of the gantry is necessary to acquire enough data for image reconstruction. Cone-beam geometry therefore has inherent quickness in volumetric data acquisition and uses a comparatively less expensive radiation detector. Herein lies its potential for significant cost savings.

There are four components to CBCT image acquisition: 1) X-ray generation, 2) Image detection, 3) Image reconstruction, and 4) Image display. It is beyond the scope of this article to detail these elements, however, it is important to recognize that the specifications of currently available systems reflect proprietary variations in these parameters.

During CBCT rotation, single exposures are made at certain degree intervals, pro-

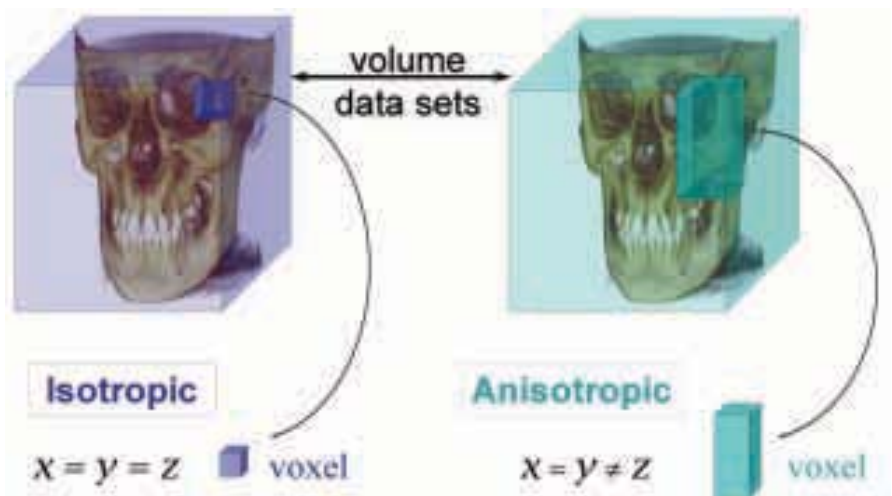


Figure 2. Comparison of volume data sets obtained isotropically (left) and anisotropically (right). Because CBCT data acquisition is dependent on the pixel size of the area detector and not on the acquisition of groups of rows with sequential translational motion, the compositional voxels are equal in all three dimensions rather than columnar with height being different from the width and depth dimensions.

Table 1. Available CBCT Imaging Systems - Worldwide

Unit	Model(s)	Manufacturer/Distributor
Accuitomo	3D Accuitomo - XYZ Slice View Tomograph/Veraviewpacs 3D	J. Morita, Japan AUS: Henry Schein Halas
Galileos	Galileos	Sirona Dental Systems, Germany AUS: Sirona Dental Systems
Hitachi	CB MercuRay / CB Throne	Hitachi Medical Systems, Japan AUS: Unknown
iCAT	i-CAT* / Platinum	Imaging Sciences Int'l, USA AUS: Body Logic Australia
ILUMA	Ultra Cone Beam CT Scanner	MTEC Imaging, USA/Kodak AUS: Currently unavailable
KaVo	3D exam * Announced at IDS 2007	KaVo, Germany AUS: Currently unavailable
Newtom	3G / NewTom VG	QR, Inc. Verona, Italy AUS: Inline Systems
Picasso Series	Trio / Pro / Master	E-Woo Technology, Korea AUS: Integradent
PreXion 3D		TeraRecon Inc., USA AUD: Currently unavailable
Promax	3D	Planmeca OY, Helsinki, Finland AUS: Henry Schein Halas
Scanora	3D CBCT	Soredex , Helsinki, Finland AUS: Currently unavailable
SkyView	3D Panoramic Imager	My-Ray Dental Imaging, Italy AUS: Currently unavailable

Table 2. Comparative Radiation Exposures from CBCT Systems

CBCT Unit		Dose ^a				
		Effective Dose (µSV)	Comparative			BERT ^b
			Imaging Surveys		No. of days	
Technique	Equivalent Panoramic Surveys ^c	% of Fan Beam CT ^d	% Annual			
CB MercuRay ^e	12-in / 9-in / 6-in FOV	477 / 289 / 169	80 / 48 / 28	22.7% / 13.8% / 8%	116 / 70 / 41	31.8% / 19.3% / 11.2%
Galileos ^e	Default / Maximum	29 / 54	5 / 9	1.3% / 2.6%	7 / 13	1.9% / 3.6%
i-Cat ^e	12-in FOV	135	23	6.4%	33	9%
Iluma ^e	Low / High	61 / 331	10 / 55	2.9% / 15.8%	15 / 81	4% / 22%
Newtom 3G ^e	12-in FOV	45	8	2.1%	11	3%
PreXion 3D ^f	Standard / High Res	69 / 160	12 / 27	3.3% / 7.6%	17 / 39	4.6% / 10.6%
ProMax 3D ^e	Small / Large	157 / 210	26 / 35	7.5% / 10%	38 / 51	10.4% / 14%

^aUsing 1990 ICRP calculations; ^bBERT=Background Equivalent Radiation Time (Macdonald, 1997) = 1.5mSv (1,500(Sv) per annum (ARPANSA, 2007).; ^cLudlow et al., 2003 - digital panoramic exposure (OrthoPhos Plus DS) = 6(Sv ; ^dNgan et al., 2002 - Maxilla and mandibular scan = 2,100µSv; ^eLudlow et al., 2006; ^fLudlow et al., 2007.

viding projection images, known as *basis* or *projection images*. These are similar to lateral, oblique, A-P and P-A “cephalometric” radiographic images, each slightly offset from one another. The complete series of images is referred to as the *projection data*. The number of images comprising the projection data, called the *frame rate* is variable, depending on the system and settings applied. The greater the frame rate for a given scan time, the more data that can be collected to construct the image. Unfortunately, while high frame rates improve image quality they increase radiation dose to the patient proportionately. Finally reconstruction software programs incorporating sophisticated algorithms including back-filtered projection are applied to these projection data to generate a three dimensional (3D) *volumetric data set*, which can be used to provide *secondary reconstruction images* in three orthogonal planes (axial, sagittal and coronal).

The resolution and therefore detail of CBCT imaging is determined by the individual volume elements or *voxels* produced from the volumetric dataset. In CBCT imaging, voxel dimensions are primarily dependent on the pixel size on the area detector, not as with conventional CT, on slice thickness. As the resolution of the area detector is sub-millimeter (range: 0.09mm to 0.4mm), this principally determines the size of the voxels. Therefore CBCT units, in general, provide voxel resolutions that are *isotropic* - i.e. equal in all three dimensions (Figure 2).

Since the introduction of the first CBCT scanner, the NewTom® QR DVT 9000 (Quantitative Radiology s.r.l., Verona, Italy), several additional systems have been marketed. Moreover additional systems are in development and are likely to be launched shortly (Table 1). All current generations of CBCT systems provide useful diagnostic images - future enhancements will most likely be directed towards reducing scan time, providing multi-modal imaging (capabilities of conventional panoramic and cephalometric as well as CBCT images), improving image fidelity including soft tissue contrast and, incorporating task specific protocols (e.g. high resolution, small FOV for dento-alveolar imaging or medium resolution, large FOV for dento-facial orthopedic imaging) to minimise patient dose.

Advantages of CBCT in dentistry

Being considerably smaller, CBCT equipment has a greatly reduced physical footprint and is approximately 20-25% of the cost of conventional CT. CBCT provides images of high contrasting structures and is therefore particularly well-suited towards the imaging of osseous structures of the craniofacial area. The use of CBCT technology in clinical dental practice provides a number of advantages for maxillofacial imaging. These include:

Rapid scan time. Because CBCT acquires all projection images in a single rotation, scan time is comparable to panoramic

radiography. This is desirable because artifact due to subject movement is reduced. Computer time for dataset reconstruction however is substantially longer and varies depending on FOV, the number of basis images acquired, resolution and reconstruction algorithm and may range from approximately 1 to 20 minutes.

Beam limitation. Collimation of the CBCT primary x-ray beam enables limitation of the x-radiation to the area of interest. Therefore an optimum FOV can be selected for each patient based on suspected disease presentation and region of interest. While not available on all CBCT systems, this functionality is highly desirable as it provides dose savings by limiting the irradiated field to fit the FOV.

Image accuracy. CBCT imaging produces images with sub-millimeter isotropic voxel resolution ranging from 0.4 mm to as low as 0.09 mm. Because of this characteristic, subsequent secondary (axial, coronal and sagittal) and MPR images achieve a level of spatial resolution that is accurate enough for measurement in maxillofacial applications where precision in all dimensions is important such as implant site assessment and orthodontic analysis.

Reduced patient radiation dose compared to conventional CT. Published reports indicate that the effective dose (*E*) varies for various full field of view CBCT

devices from 29-477 μSv depending on the type and model of CBCT equipment and FOV selected (Table 2) (Schulze et al., 2004; Mah et al., 2003; Ludlow et al., 2003, 2006, 2007). Patient positioning modifications (tilting the chin) and use of additional personal protection (thyroid collar) can substantially reduce dose by up to 40% (Ludlow et al., 2006). These doses can be compared more meaningfully to dose from a single digital panoramic exposure (Ludlow et al., 2003), equivalent CT dose (Ngan et al., 2002), or the average natural background radiation exposure for Australia (1,500 μSv) (ARPANSA, 2007) in terms of background equivalent radiation time (BERT) (MacDonald, 1997). CBCT provides an equivalent patient radiation dose of 5 to 80 times that of a single film-based panoramic radiograph, 1.3% to 22.7% of a comparable conventional CT exposure or 7 to 116 days of background radiation (Table 2).

Interactive display modes unique to maxillofacial imaging. Perhaps the most important advantage of CBCT is that it provides unique images demonstrating features in 3D that intraoral, panoramic and cephalometric images cannot. CBCT units reconstruct the projection data to provide inter-relational images in three orthogonal planes (axial, sagittal and coronal). In addition, because reconstruction of CBCT data is performed natively using a personal computer, data can be reoriented such that the patient's anatomic features are realigned. Basic enhancements include zoom or magnification, window/level and the capability to add annotation. Cursor-driven measurement algorithms provide the clinician with an interactive capability for real-time dimensional assessment. On-screen measurements provide dimensions free from distortion and magnification. Because of the isotropic nature of the volumetric dataset, data sets can be sectioned non-orthogonally, referred to as *multi-planar reformation* (MPR). Such MPR modes include oblique, curved planar reformation (providing "simulated" distortion free panoramic images) and, serial trans-planar reformation (providing cross-sections), all of which can be used to highlight specific anatomic regions and diagnostic tasks (Figure 3). This is important given the complex structure of the

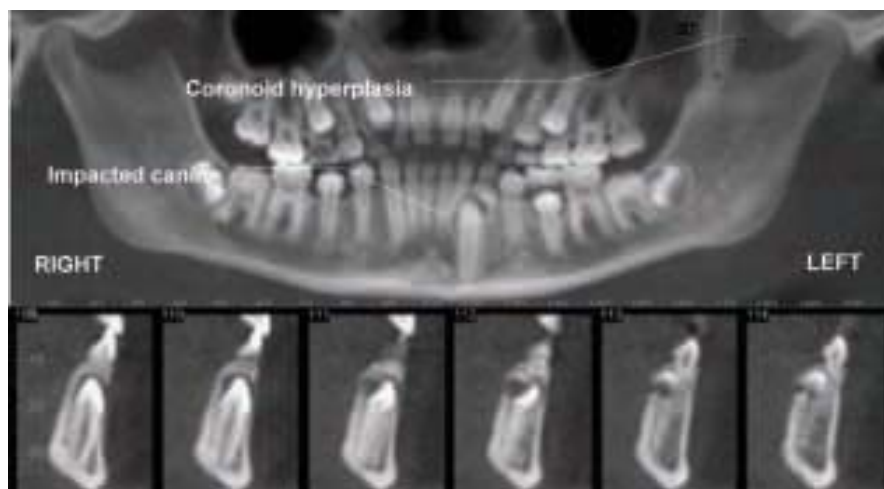


Figure 3. Curved multi-planar reformatted (MPR) simulated "panoramic" image from CBCT showing left sided hypertrophy of the coronoid process and impaction of the mandibular left canine (top). Sequential cross-sectional images of the impacted tooth show buccal eruption and location of the impacted tooth relative to deciduous teeth (Data acquired and images generated using i-CAT).

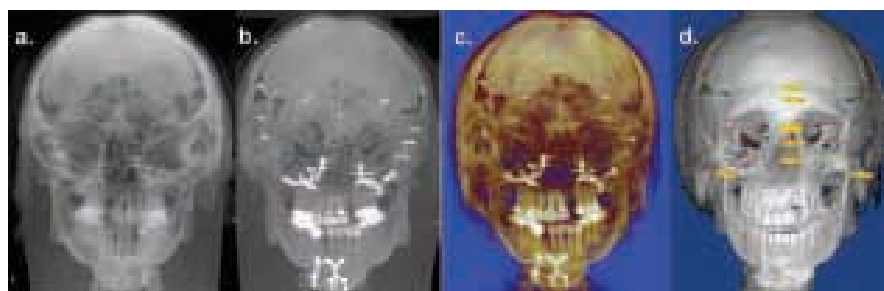


Figure 4. Comparison of 3D visualization techniques applied to CBCT dataset of a patient with a craniofacial deformity: Ray sum (a); maximum intensity projection (b); and 3D computer generated modeling including volumetric transparent and shaded surface display (c). 3D cephalometric measurements can be performed interactively on the volumetric representations (d) (Volumetric data set acquired with extended field of view i-CAT and all reconstructions generated using Dolphin 3D).

maxillofacial region. Finally techniques are available that provide true 3D visualization of the dataset including ray sum, maximum intensity projection and 3D computer generated models (Figure 4).

Limitations of CBCT imaging

While there has been enormous interest, current CBCT technology has limitations related to the "cone beam" projection geometry, detector sensitivity and contrast resolution. These parameters create an inherent image "noise" that reduces image clarity such that current systems are unable to record soft tissue contrast at the relatively low dosages applied for maxillofacial imaging. Another factor that impairs CBCT image quality is image artifact such as streaking, shading, rings and

distortion. Streaking and shading artifacts due to high areas of attenuation (such as metallic restorations) and inherent spatial resolution may limit adequate visualization of structures in the dento-alveolar region.

Applications

Currently CBCT is most commonly used in the assessment of bony and dental pathologic conditions including fracture, structural maxillofacial deformity and fracture recognition, preoperative assessment of impacted teeth, TMJ imaging (Figure 5) and in the analysis of available bone for implant placement (Figure 6). In orthodontics, CBCT imaging is now being directed towards 3D cephalometry.

The availability of CBCT is also expanding the use of additional diagnostic

and treatment software applications - all directed towards 3D visualization. This is because CBCT data can be exported in the non-proprietary DICOM (Digital Imaging and Communications in Medicine) file format standard. CBCT permits more than diagnosis, it facilitates imaged guided surgery. Diagnostic and planning software is available to assist in orthodontic assessment and analysis (e.g. Dolphin 3D, Dolphin Imaging, Chatsworth, CA, USA) and implant planning to fabricate surgical models (e.g. Biomedical Modeling Inc., Boston, MA, USA), facilitate virtual implant placement, create diagnostic and surgical implant guidance stents (e.g. Virtual Implant Placement (VIP); Implant Logic Systems, Cedarhurst, NY, USA; Simplant; Materialise, Leuven, Belgium) Figure 7), and even assist in the computer aided design and manufacture of implant prosthetics (NobelGuide/Procera software; Nobel Care AG, Göteborg, Sweden). Software is also available to provide surgical simulations for osteomies and distraction osteogenesis (Maxilim; Medicim NV, Mechelen, Belgium). This is a blossoming field which provides opportunities for practitioners to combine CBCT diagnosis, 3D simulations, with virtual surgery and computer assisted design and manufacturer. Image-guidance is an exciting advance that will undoubtedly have substantial impact on dentistry.

Clinical implications

The impact of CBCT technology on maxillofacial imaging since its introduction cannot be underestimated. This does not imply that CBCT is appropriate as an imaging modality of first choice in dental practice. However there are no published specific patient selection criteria for the use of CBCT in maxillofacial imaging - guidelines as to the when, where, why, what, how and on whom. As cone beam exposure provides a radiation dose to the patient higher than any other imaging procedure in dentistry it is paramount that practitioners abide by the Code of Practice: Radiation Protection in Dentistry in that a responsible person keep radiation exposure ALARA (As Low As Reasonably Achievable) (Loy, 2005). The basis of this is that there should be justification of the exposure to the patient such that the total potential diagnostic benefits are greater

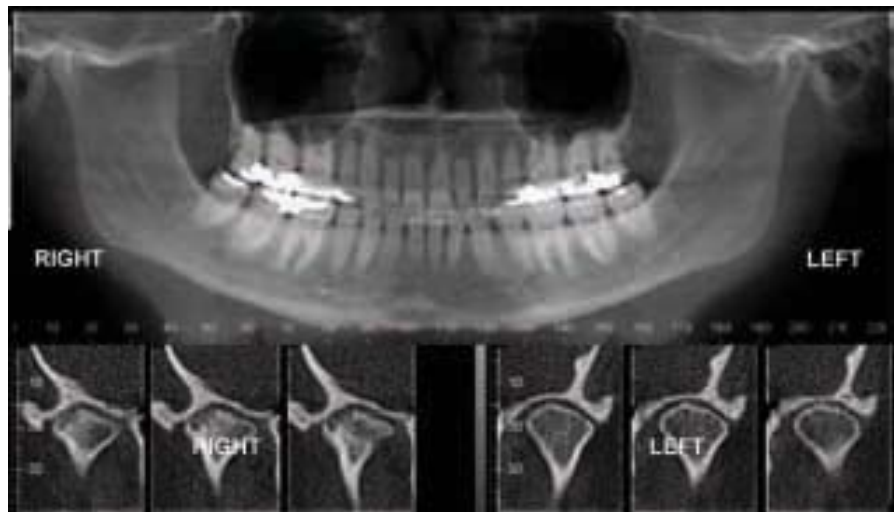


Figure 5. CBCT applications in TMJ assessment. Reformatted 'panoramic' image (top) showing right side condyle differences in shape compared to normal left. Cropped para-coronal reformatted images clearly showing subcortical cystic defects in surface of right condyle as compared to the left indicative of active degenerative joint disease. (Volumetric data set acquired with iCAT).

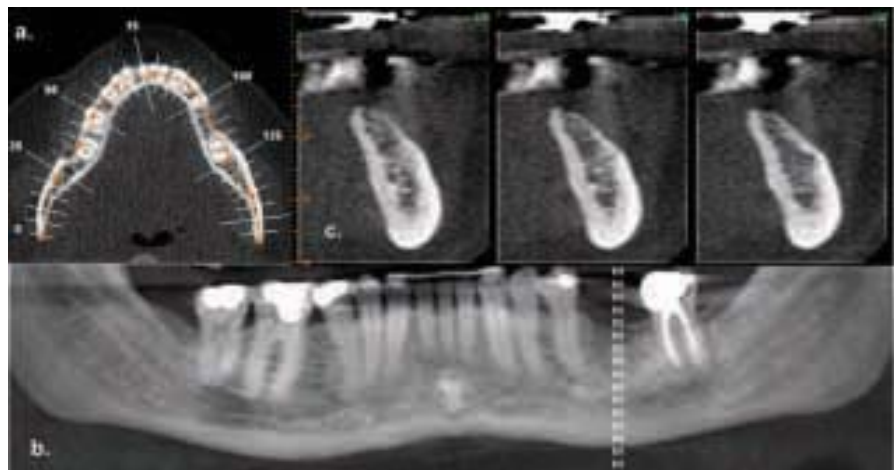


Figure 6. CBCT applications in implant site assessment. A curved planar MPR is accomplished by aligning the long axis of the imaging plane with the dental arch (a.), providing a region panorama-like thin-slice image (b). In addition serial thin slice trans-planar images are generated (c.), useful in the assessment of specific morphologic features such as the location of the inferior alveolar canal for implant site assessment as well as allowing measurement so the available alveolar bone height and width. (Volumetric data set acquired with iCAT).

than the individual detriment radiation exposure might cause. CBCT should not be considered a replacement for standard digital radiographic applications that, ironically, also use a cone beam of radiation, but without computed integration of basis projections. Rather, CBCT is a complementary modality for specific applications.

While deceptively relatively simple, the technical component of patient exposure is only one half of cone beam imaging. Based

on the medical model of imaging, there is also a moral, ethical and legal responsibility of interpretation of the resultant volumetric dataset (Holmes, 2007; Turpin, 2007; Loy, 2005). The mechanics of interpretation involve image reporting with the development of a series of images formatted to display the condition/region appropriately (image report) and a cognitive interpretation of the significance of the imaging findings (interpretive report).

Towards Voxel Vision...

Clinical applications of cone beam imaging in dental practice

Presented by

Prof. William C Scarfe

Gold Coast	10 August 2007
Melbourne	14 August 2007
Sydney	15 August 2007

For more info or to register, call
Body Logic Australia
on (07) 5562-0355

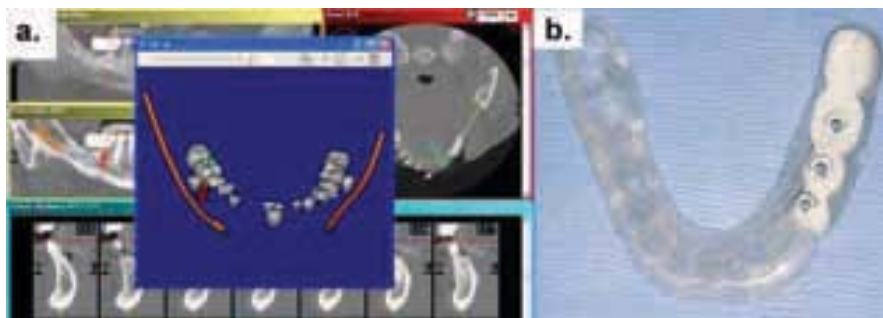


Figure 7. Virtual implant placement and surgical guidance using CBCT: (a.) Screen of implant placement software (VIP, Implant Logic Systems, Cedarhurst, NY) with multiple projections relating prosthetic placement of teeth with important anatomic structures, and locating implants in 3D and (b.) Surgical guidance stent for implant placement manufactured from planning performed using VIP software. (Courtesy of Dr Michael Klein, Implant Logic Systems, Cedarhurst, NY).

These skills are not within the domain of most general and specialist practitioners however act as the *de facto* standard of care in providing CBCT services. It would behoove those contemplating or currently using CBCT imaging to develop and maintain these skills by self study of journal articles and participation in study groups or attendance at continuing education courses.

Conclusion

The development and rapid commercialization of CBCT technology dedicated for use in the maxillofacial region will undoubtedly increase both general and specialist practitioner access to this

imaging modality. CBCT is capable of providing accurate, sub-millimetre resolution images in formats enabling 3D visualization of the complexity of the maxillofacial region. Increasing availability of this technology provides the practitioner with a modality that is extending maxillofacial imaging from diagnosis to image guidance of operative and surgical procedures.

CPD POINTS AVAILABLE

Continuing Education credits are available on this article for subscribers by answering the questionnaire at www.dentalpractice.com.au

References

- Australian Radiation Protection and Nuclear Safety Agency (ARPANSA). Ionising Radiation and Health www.arpansa.gov.au/radiationprotection/Factsheets/is_rad.cfm Accessed July 5, 2007.
- Holmes SM. iCAT Scanning in the Oral Surgery Office. OMS National Insurance Company Newsletter 2007;18:
- Loy J. Code of Practice. Radiation Protection in Dentistry. Radiation Protection Series Publication No. 10 Australian Radiation Protection and Nuclear Safety Agency (ARPANSA) 2005. ISBN 0-9758169-2-6
- Ludlow JB, Davies-Ludlow LE, Brooks SL. Dosimetry of two extraoral direct digital imaging devices: NewTom cone beam CT and Orthophos Plus DS panoramic unit. *Dentomaxillofac Radiol* 2003;32:229-34.
- Ludlow JB, Davies-Ludlow LE, Brooks SL, Howerton WB. Dosimetry of 3 CBCT devices for oral and maxillofacial radiology: CB Mercuray, NewTom 3G and i-CAT. *Dentomaxillofac Radiol*. 2006;35:219-26. Erratum in: *Dentomaxillofac Radiol*. 2006;35:392.
- Ludlow JB, Davies-Ludlow LE, Mol A. Dosimetry of recently introduced CBCT units for oral and maxillofacial radiology. *Proceedings of the 16th International Congress of Dentomaxillofacial Radiology*, Beijing, China 26-30 June, 2007 p.97
- Macdonald R. Have you met BERT? *Aust Dent Assoc (SA) Newsletter* 1997;10(9):8-9
- Mah JK, Danforth RA, Bumann A, Hatcher D. Radiation absorbed in maxillofacial imaging with a new dental computed tomography device. *Oral Surg Oral Med Oral Pathol Oral Radiol Endod* 2003;96:508-13.
- Ngan DC, Kharbanda OP, Geenty JP, Darendeliler MA. Comparison of radiation levels from computed tomography and conventional dental radiographs. *Aust Orthod J* 2003;19:67-75.
- Schulze D, Heiland M, Thurmann H, Adam G. Radiation exposure during midfacial imaging using 4- and 16-slice computed tomography, cone beam computed tomography systems and conventional radiography. *Dentomaxillofac Radiol* 2004;33:83-6.
- Turpin DL. Befriend your oral and maxillofacial radiologist. *Am J Orthod Dentofacial Orthop* 2007;131:697.

About the authors

Professor William Scarfe graduated from the University Of Adelaide School Of Dentistry (1982) and was awarded Fellowship in the Royal Australasian College of Dental Surgeons (1986). He completed a certificate in Dental Diagnostic Science and a Masters from the Graduate School at the University of Texas Health Science Center at San Antonio (1992). He is currently Professor of Radiology and Imaging Science, Dept of Surgical and Hospital Dentistry, The University of Louisville and Diplomate of the American Board of Oral and Maxillofacial Radiology, a specialist OMF radiologist and co-director of Diagnostic Maxillofacial Imaging University Associates (www.dmfua.com), a university-based, private cone beam imaging facility established in 2004. Dr Scarfe is North American Regional Director of the International Association of Dento-Maxillo-Facial Radiology, and Treasurer, American Academy of Oral and Maxillofacial Radiology. He is on the editorial board of the *Radiology Section of Oral Surgery Oral Medicine Oral Pathology Oral Radiology and Endodontics (OOOOE)*.

Professor Allan Farman is a Professor of Radiology and Imaging Science, Dept of Surgical and Hospital Dentistry, The University of Louisville and a Diplomate of the American Board of Oral and Maxillofacial Radiology. He is a co-director of Diagnostic Maxillofacial Imaging University Associates. Dr Farman is Editor of the *Radiology Section of OOOE and Cranio* as well as a Representative for the American Dental Association to the International DICOM Standards Committee. He also founded and Chairs the International Congress and Exposition on Computed Maxillofacial Imaging.